

Recognition, Treatment & Reconditioning of Shoulder Instability

Taylor Purchio MS, LAT, ATC



ATHLETIC MEDICINE
& PERFORMANCE

OBJECTIVES

1. Recall basic anatomy of the shoulder
2. Discuss athletic injuries related to each case
3. Examine evaluations, treatments and pertinent taping & bracing techniques



CONFLICT OF INTEREST

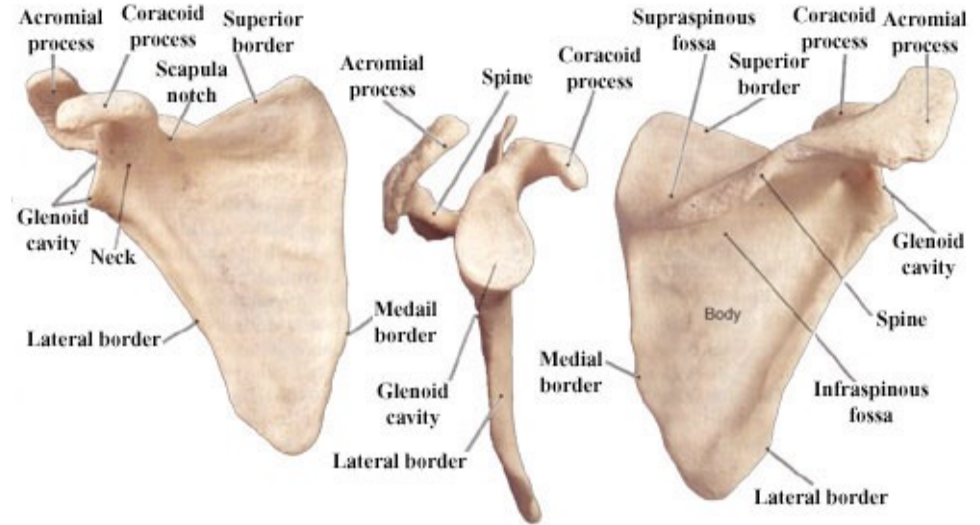
- I am an employee at Ortho Montana & Athletic Medicine and Performance (AMP)
- No financial compensation to disclose



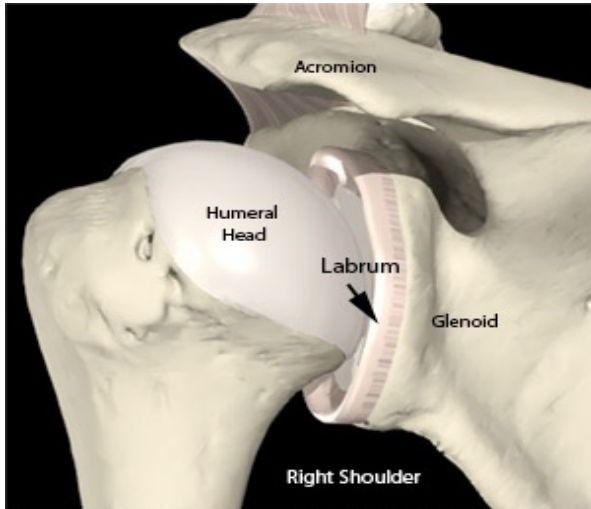
SHOULDER ANATOMY

Shoulder Girdle

- Formed by 4 bones:
 1. Clavicle
 2. Scapula
 3. Sternum
 4. Humerus



SHOULDER ANATOMY



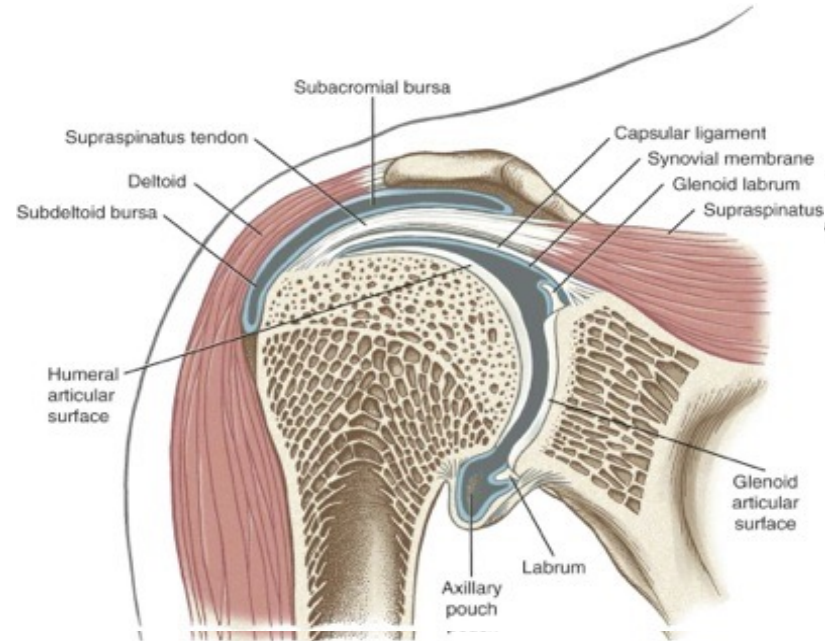
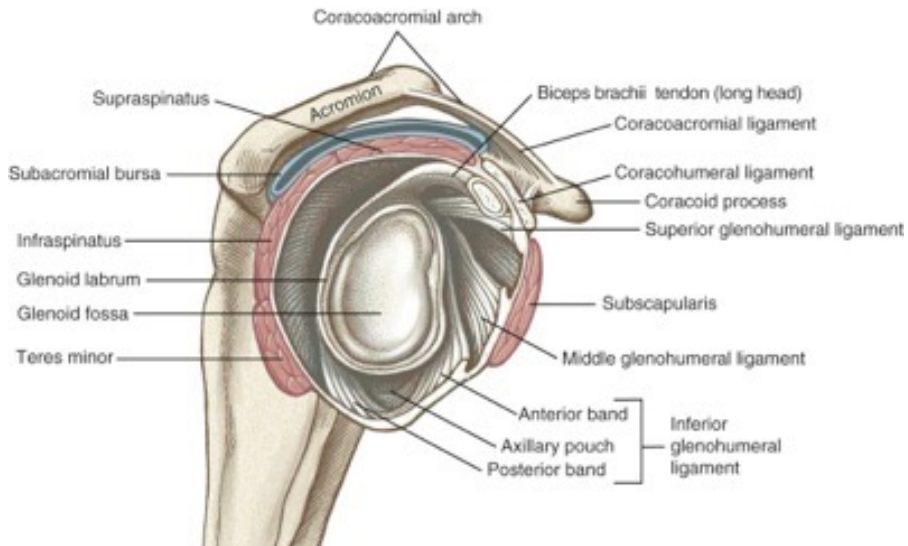
Interactive Shoulder v1.0 © 2000 Primal Pictures Ltd.

4 Joints of the Shoulder Complex

1. **Glenohumeral**
2. **Scapulothoracic**
3. **Acromioclavicular**
4. **Sternoclavicular**



SHOULDER ANATOMY



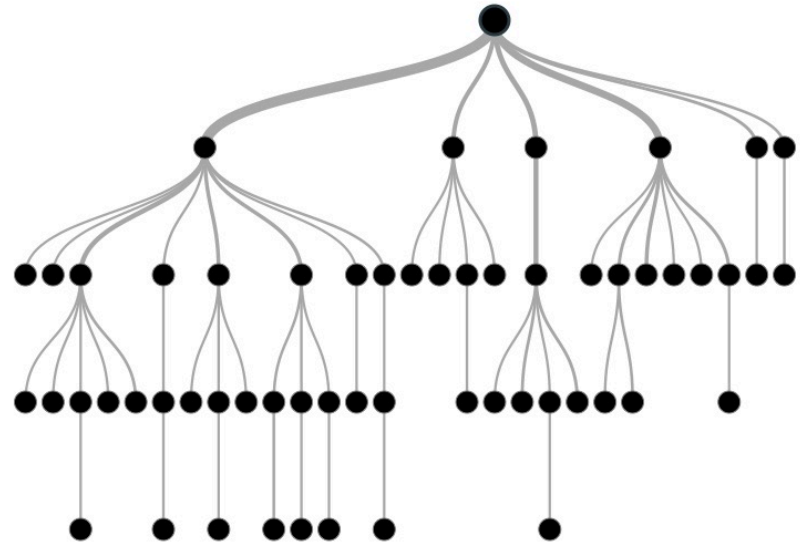
SHOULDER EVALUATION — KEY HISTORY ?'S

- Chief Complaint
- Side of Dominance
- Mechanism
 - FOOSH?
- Pain
 - Location, type, severity
 - Radiates, refers, radicular
- Neurological Symptoms
- Movements and Activities that cause pain
 - Specific motion or phase of activity?
- Previous Injury
 - Recurrent dislocation/subluxation
 - Specific MOI/Onset?
 - What Direction? Difficulty Relocating?
- Imaging and Treatment



SHOULDER EVALUATION – BRANCHING DECISION TREE

- Glenohumeral Instability
- Rotator Cuff
- Labral Pathology
- Impingement
- Scapular Pathology
- Biceps Pathology



SHOULDER EVALUATION — ON-FIELD EVALUATION

Inspection & Palpation

- Position of GH joint/Humeral Head
- Gross deformity
- Muscle tone/spasm
- Step-off deformity/Piano Key Sign

Range of Motion & Muscle Testing

- Apley's Scratch Test
- Flexion & Extension
- Abduction & Horizontal Adduction
- Internal & External Rotation

- Deltoid
 - Anterior, Middle, Posterior
- Trapezius
 - Upper, Middle, Lower



SHOULDER EVALUATION – SIDELINE/CLINICAL EVALUATION

Special Tests – GH Instability

- Anterior Apprehension & Relocation
- Anterior Release
- Posterior Apprehension
- Jerk Test
- Load & Shift
- Posterior Clunk
- Feagin's Test
- Sulcus Sign

Special Tests – RTC & Labral Pathology

- Anterior Slide
- O'Brien's Test
- Compression-Rotation Test
- Gerber Lift-Off
- Belly Press



CASE PRESENTATIONS — PATIENT #1

16-year-old Female Athlete

- 2 Sport Athlete
 - CC: Right Shoulder Instability
- Timeline
 - DOI: (1/11/2019)
 - Referred out to ER immediately
 - DOS: (2/11/2019)
 - Cleared to Return: (11/21/2019)



CASE PRESENTATION — PATIENT #1



17-year-old Female Athlete

- Day 1 of Basketball Tryouts
 - Posterior Dislocation
- Timeline
 - DOI: (11/26/2019)
 - Referred out to Dr. Klepps
 - DOS: (5/25/2020)



CASE PRESENTATIONS — PATIENT #2

14-year-old Male Athlete

- 2 Sport Athlete
 - CC: Right Shoulder Instability
- Timeline
 - DOI: (7/21/2017)
 - DOSI: (8/4/2017)
 - Date of Surgery: (8/12/2017)



CASE PRESENTATION — PATIENT #2



17-year-old Male Athlete

- Anterior Dislocation sliding into 2nd base
- Subsequent Dislocations Throughout Remainder of Baseball Season
- Timeline
 - DOI: (5/22/2020)
 - Referred out to Dr. Klepps
 - DOSI: (8/9/2020)
 - Date of Surgery: (11/9/2020)



POSSIBLE TAPING & BRACING SOLUTIONS

